

Surgical Considerations and Decision Making in Surgically Facilitated Orthodontic Treatment/Periodontally Accelerated Osteogenic Orthodontics

George A. Mandelaris,^{*†‡} Colin Richman[§] and Richard T. Kao^{||¶}

Focused Clinical Question: Surgically facilitated orthodontic treatment (SFOT)/periodontally accelerated osteogenic orthodontics (PAOO) has the potential of allowing safer orthodontic treatment in vulnerable periodontium with thin phenotypes. SFOT/PAOO is a phenotype modification therapy (PhMT) approach where thin bone morphotype and/or gingiva are surgically augmented to convert a fragile-thin to a robust-thick periodontal environment. This permits orthodontic treatment in these previously thin phenotype cases to proceed without iatrogenically-induced adverse effects. This is an infrequently performed procedure with few available clinical recommendations.

Summary: In this practical application paper, three clinicians with the collective clinical experience of over 1500 SFOT cases developed a clinical decision-making algorithm outlining the key steps for SFOT. A sample case is provided for clinical appreciation of the procedure. Lastly, this panel reviewed and detailed the critical decision making and surgical approaches associated with the use of SFOT. Though the basic decision making is consistent, individual variations on surgical management are compared. This is summarized in a clinical decision tree along with a sample clinical case. Additionally, the cumulative experience has been organized into tables that provide comparative decision and surgical approaches. There are similarities and differences. Lastly, strategies that have not been individually effective are also noted.

Conclusion: SFOT/PAOO is an effective PhMT approach whereby the bone and/or soft tissue phenotype can be surgically modified to permit orthodontic treatment in patients with thin phenotypes. The cumulative experience of three experienced clinicians provides clinical recommendations for SFOT management of PhMT for pre-orthodontic treatment. *Clin Adv Periodontics* 2020;0:1–11.

Key Words:

Background

Orthodontic treatment is limited by the inherent regional hard and soft tissue anatomy within any individual. This BEC paper focuses on surgical phenotype modification therapy (PhMT) in concert with orthodontic treatment.

^{*}Periodontics and Oral Medicine, University of Michigan, Ann Arbor, MI

[†]Graduate Periodontics, University of Illinois, Chicago, IL

[‡]Private practice, Chicago, IL

[§]Private practice, Atlanta, GA

^{||}Orofacial Sciences, University of California San Francisco, San Francisco, CA

[¶]Private practice, Cupertino, CA

Equal contributions for chart and treatment review. Decision tree and comparative management table development were coordinated by RT Kao.

Practical Applications to be part of BEC Series on modifying gingival phenotype in preparation for orthodontic treatment

Received December 2, 2019; accepted June 11, 2020

doi: 10.1002/cap.10116

Although the modification of soft tissue through various augmentative procedures has been extensively detailed at the 2014 Regeneration Workshop,^{1,2} orthodontic treatment may require bone augmentation of the osseous housing and, at times, increasing the gingival tissue thickness. This is necessary such that orthodontic tooth movement does not result in increased development of bony dehiscence and fenestration and potential gingival recession, mobility, and create risk for future recession-based attachment loss.

Surgically facilitated orthodontic therapy (SFOT) is a surgical procedure which can permit the pursuit and completion of more complicated orthodontic cases in an area with minimal or inadequate soft and hard tissue volume.^{3–5} SFOT describes a broad category of surgical procedures that can facilitate and support orthodontic therapy. This would include the use of corticotomy surgery plus dentoalveolar bone decortication with bone augmentation ± gingival grafting which has been popularized as periodontally accelerated osteogenic orthodontics (PAOO). As a broader category, SFOT also includes the use of temporary anchorage device (TAD) and/or anchor plates. The term PAOO has been described by others under the patented name of accelerated osteogenic orthodontics (AOO) or Wilcodontics. In this article, SFOT

Decision Tree for SFOT/PAOO

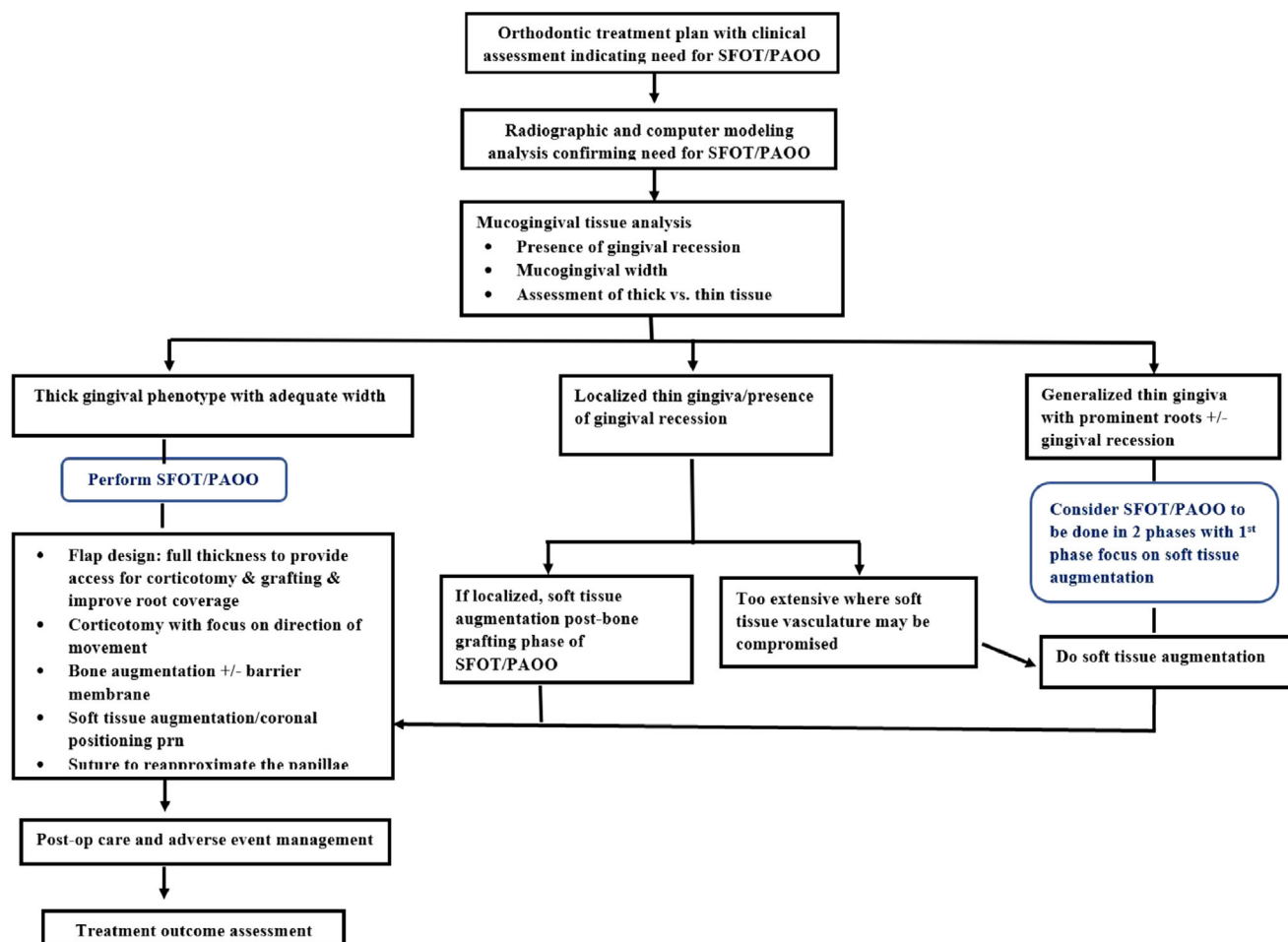


FIGURE 1 Decision tree for SFOT/PAOO.

will focus on the use of dento-alveolar corticotomy surgery with dentoalveolar bone decortication and bone augmentation to facilitate orthodontic treatment \pm soft tissue grafting.³ This procedure is efficacious in the treatment of malocclusion by increasing alveolar volume and enhancing periodontal phenotypes.³ It can also be effective in the management of dentoalveolar deficiencies that when tooth movement exceeds the orthodontic boundary conditions.⁶⁻⁹ The benefits of SFOT include accelerated treatment time,⁶ greater stability of clinical outcome with less relapse,¹⁰ and enhanced the scope of treatment for malocclusion.³ Clinically, SFOT has been shown to resolve crowding of the natural dentition,⁴ facilitate eruption of impacted teeth,¹¹ accelerate canine retraction,⁴ intrusion, and open bite correction,^{3,8} and facilitate borderline orthognathic/orthodontic surgical cases.¹² With bone augmentation that is performed in conjunction with the corticotomy surgery, the increased thickness of the alveolar bone is believed to enhance post-orthodontic stability of the dentition.¹³⁻¹⁵ In a 2016 systematic review,⁶ corticotomy did not result in negatively influencing periodontal health, including periodontal probing depth, gingival recession, clinical attachment levels, and alveolar crestal bone heights.

Whereas the treatment planning of these cases is complicated, as described in the previous paper,⁷ the surgical operational aspect of the procedure is familiar and highly suited to periodontists with advanced training in this therapeutic modality. In this paper, three experienced clinicians with at least over 1500 collective cases have developed a decision tree for SFOT, and shared their surgical experiences and various management approaches. It is the objective of this BEC series to have the profession develop a familiarity, level of comfort, and an appreciation for the treatment in managing this type of interdisciplinary treatment requiring SFOT.

Decision Process

In the orthodontic management of thin phenotype cases, the critical decision is to determine if the periodontal phenotype has adequate soft tissue (keratinized tissue width and gingival thickness) with a bone morphotype that will be conducive to the planned tooth movement. Depending on the extent of the thin soft tissue morphology, the soft tissue augmentation may be performed simultaneously with corticotomy surgery and bone

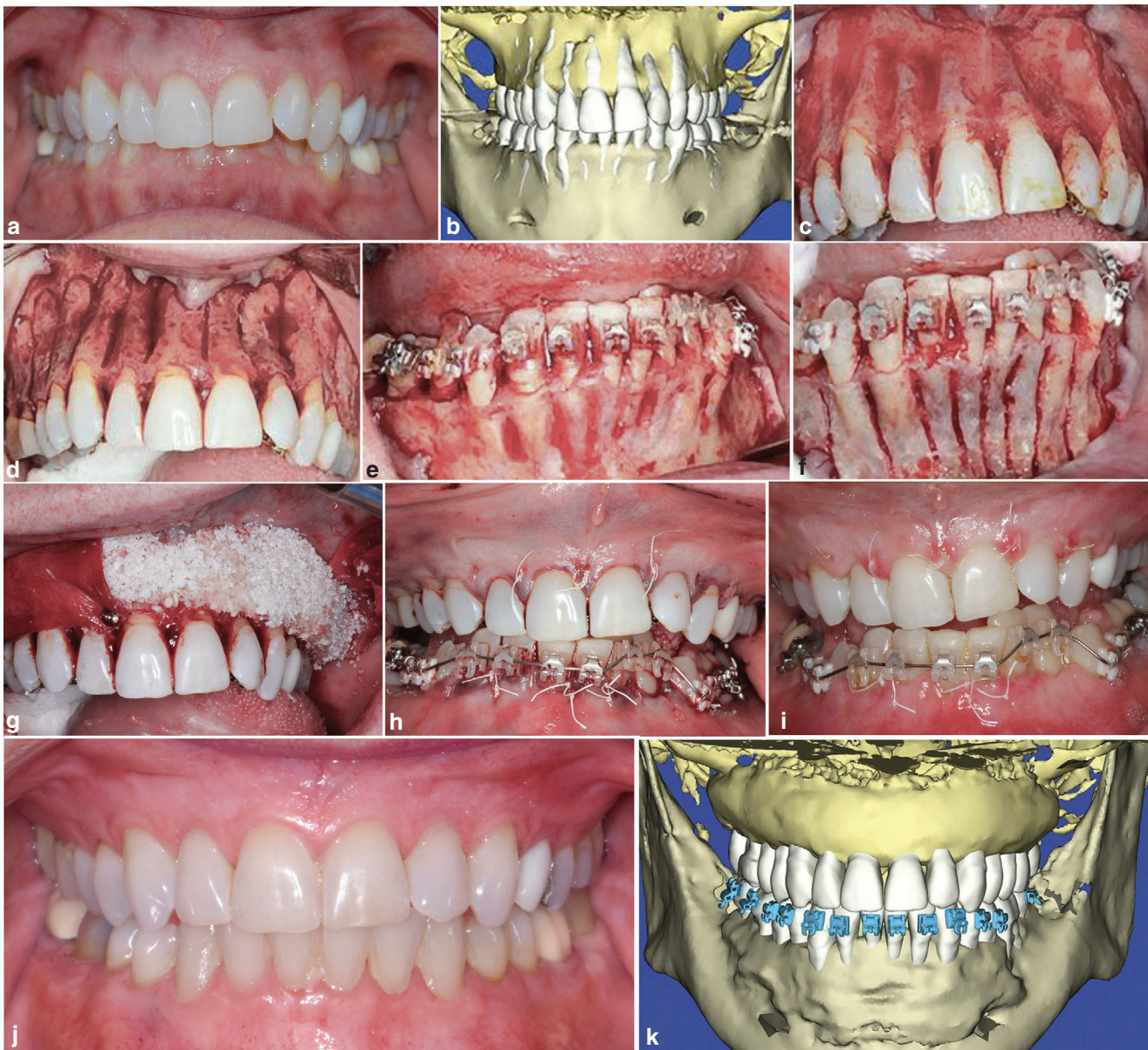

FIGURE 2 Detailed steps of SFOT/PAOO. a) pre-op clinical view; b) pre-op computer analysis of CBCT (note the prevalence of fenestration and dehiscence- dentoalveolar deficiencies); c) surgical view- maxillary view; d) maxilla with corticotomy; e) surgical view-mandibular view; f) mandible with corticotomy; g) bone augmented maxilla with portions covered with collagen barrier membrane; h) closure with ePTFE sutures; i) 1 wk. post-op; j) case completion; and k) post-op computer analysis of CBCT.

augmentation or can be addressed as a preliminary preparatory surgical procedure. In this latter situation, an additional 3 months of healing is required. In [Fig. 1](#), the panel jointly developed a decision tree for SFOT with or without soft tissue augmentation. Additionally, the panelists compared and contrasted their various approaches to SFOT.

Clinical Scenarios

In the treatment of thin phenotype cases requiring tooth movement, orthodontic treatment may require SFOT. Should the overlying gingival tissue be suspected to be inadequate to support the bone augmentation, PhMT

may require surgical correction or embellishment of the mucogingival tissue. This often involves soft tissue augmentation using autogenous or tissue substitute materials. If localized, this may be addressed during the corticotomy-bone augmentation phase of SFOT. If the gingival tissue is thin in a generalized fashion, preliminary soft tissue augmentation/embellishment may be beneficial ([Fig. 1](#)).

Critical stages for the management of PhMT in thin phenotype cases involve an interdisciplinary assessment of the osseous and mucogingival tissue, the scope of proposed orthodontic tooth movement, the actual corticotomy-bone augmentation procedure, and post-operative care as detailed in [Fig. 2](#). There are many commonalities in the therapeutic approaches by each

TABLE 1 Comparison of soft tissue assessment and management by the panelist

Procedure	Op 1	Op 2	Op 3
Pre-sx consultation with orthodontist	<ul style="list-style-type: none"> ■ Clinical exam/CBCT ■ Consultation with orthodontist ■ Confirm detailing needs timing, and responsible party for TADs and OGS ■ Pre-operative s/rp, prophyl, and OHI 2 weeks prior to surgery 	<ul style="list-style-type: none"> ■ Clinical exam/CBCT ■ Consultation with orthodontist ■ Confirm detailing needs timing, and responsible party for TADs and OGS ■ Pre-surgical hygiene visit: s/rp and prophyl for 1 to 2 session. with staining and OHI. Stain for plaque index. 	<ul style="list-style-type: none"> ■ Clinical exam/CBCT ■ Consultation with orthodontist ■ Confirm detailing needs timing, and responsible party for TADs and OGS ■ Pre-surgical hygiene visits within 1 week of surgery
Assessment of muco-gingival conditions	<ul style="list-style-type: none"> ■ Mucogingival status is evaluated per 2014 AAP Regeneration Workshop. ■ Evaluate if there are areas of thin gingival phenotype (as defined by perio probe visibility test)/with existing gingival recession. ■ Localized versus generalized. If generalized, conversation is about 2 phases with soft tissue graft to thicken gingival thickness and a secondary phase for corticotomy and bone grafting procedure 	<ul style="list-style-type: none"> ■ Mucogingival status is evaluated per 2014 AAP Regeneration Workshop. ■ Evaluate if there are areas of thin gingival phenotype (as defined by perio probe visibility test)/with existing gingival recession. ■ Localized versus generalized. If generalized, conversation is about 2 phases with soft tissue graft to thicken gingival thickness and a secondary phase for corticotomy and bone grafting procedure 	<ul style="list-style-type: none"> ■ Mucogingival status is evaluated as per 2014 AAP Regeneration Workshop. ■ Evaluate if there are areas of thin phenotype (as defined by perio probe visibility test)/with existing gingival recession ■ If recession, classify as Miller I-IV defect and root coverage predictability ■ Localized versus generalized ■ Many soft tissue considerations may be managed at the time of SFOT. However, aberrant frenum and more extensive recession or phenotype concerns are managed 12 weeks prior to SFOT surgery ■ NCCL may be managed with bonding after SFOT surgery to establish the correct CEJ position
Grafting strategy	<ul style="list-style-type: none"> ■ SCTG (primary) Type of tissue used for gingival grafting: subepithelial connective tissue graft that's harvested from the palate as FGG which is subsequently de-epithelialized with either dermal abrasion with surgical round diamond or ablation with NdYAG laser ■ FGG (occasionally for mandibular arch) 	<ul style="list-style-type: none"> ■ FGG ■ Acellular dermal matrix¹ for containment, thicken, for frenum 	<ul style="list-style-type: none"> ■ Aberrant frenum removed prior to surgery with FGG ■ Soft tissue embellishment with acellular dermal matrix¹ (generalized arch need) or SCTG is more localized

(Continued)

TABLE 1 (Continued)

Procedure	Op 1	Op 2	Op 3
Surgical complications	<ul style="list-style-type: none"> ■ Surgical complications experienced: <ol style="list-style-type: none"> Inadequate soft tissue harvested. Managed by using collagen matrix² or secondary SCTG grafting Inadequate root coverage resolved by coronal repositioning Localized sloughing of the epithelium Delay of corticotomy phase by 3 to 4 months while the grafted area revascularize 	<ul style="list-style-type: none"> ■ Areas of gingival sloughing w granulation tissue move up ■ Touch up for inadequate gingival cover-inlay/only FGG ■ Rarely, contamination associated with acellular dermal matrix exposure and used 2 × 2 to milk suppuration ■ Usually on extremely very thin cases with extensive mucosal tissue so blood supply unable to support ■ Use autogenous FGG ■ Tend to use 2nd rehydration / wash with venous blood 	<ul style="list-style-type: none"> ■ Complications may include early, moderate or late phase infection usually associated with the bone grafting. The may require I and D or open flap surgery and debridement/graft removal and revision as required ■ Flap dehiscence/perforation leading to mucogingival and/or bone graft problems. Lack of graft containment and poor or failed regenerative result outcome realized. ■ Delayed wound healing with possible worse mucogingival status, pulpal involvement, tooth loss or bone segment sloughing/loss ■ One case of advanced root resorption
Pre-op meds and preparation	<ul style="list-style-type: none"> ■ Clearance for sedation ■ Orthodontic brackets in place 1 to 2 weeks prior ■ Pre-sx med: Ibuprofen (600 mg q6h) start 48 hours prior to surgery ■ CHX at time of surgery for 3 minutes 	<ul style="list-style-type: none"> ■ Clearance for sedation ■ Orthodontic brackets/aligners in place 2 weeks prior ■ Pre-sx med: if not IV ibuprofen + extra strength acetaminophen + antibiotic ■ 6 Norco prn for pain but seldom used ■ Toradol for IV sedation 	<ul style="list-style-type: none"> ■ Clearance for sedation ■ Orthodontic brackets/aligners in place ■ Pre-sx med: Amoxicillin 2.0 g 1 hour op prior or 600mg cefocin 1 hour prior. If general anesthesia, antibiotics are given IV at surgery ■ Pre-sx restorative phase completed
Sedation	<ul style="list-style-type: none"> ■ Mostly LA ■ LA ± some oral sedation w 0.25 mg triazolam + 5 mL midazolam HCL syrup (2 mg/mL) or IV sedation valium – versed combination 	<ul style="list-style-type: none"> ■ LA ± sedation administer by nurse anesthetist 	<ul style="list-style-type: none"> ■ LA with IV sedation performed by Dr and nurse or dental anesthesiologist. Sometimes in combination with oral sedation (0.25 mg Halcion) ■ General anesthesia via nasal intubation for secure airway by dental anesthesiologist

■ Highlighted procedures are common therapeutic approaches shared by all.

OGS = orthognathic surgery; TAD= temporary anchorage devices.

Alloderm; 2. Mucograft; 3. Osteoceil; 4. PDGF; 5. Endogain; 6. PrefGel; 7. BioOss; 8 BioGid.

panelist; however, there are individual preferences especially in terms of surgical supplies as noted in [Tables 1 to 3](#). The extensive experience of the group has also identified strategies that may improve, along with those that do not enhance clinical outcomes. Once the soft tissue has been determined to be adequate to support the corticotomy-bone augmentation phase, several critical steps have been defined for successful outcomes. A clinical case is provided to define these steps (see [Fig. 2](#) for clinical case).

Discussion

Orthodontic treatment limitation is usually based on the extent of the proposed orthodontic tooth movement and osseous boundaries as defined by the CBCT analysis.⁶⁻⁹ The extent of tooth movement is somewhat subjective and variable as the modulus of elasticity of dentoalveolar bone (in vivo and in humans) has no consensus. Proffit's envelope of discrepancy can be cited for some direction on malocclusion case management, but these numbers do not consider opportunities when dentoalveolar bone augmentation has been performed.¹⁶ Ferguson et al. published on the scope of treatment with periodontally accelerated osteogenic orthodontic therapy and reported that certain tooth movements can be 2× to 3× greater than of conventional orthodontic parameters, from a horizontal (bucco-lingual) or vertical.³ The extent of tooth movement and need for dentoalveolar bone augmentation is best evaluated with 3D simulation technology that allows the dentoalveolar bone complex to be scrutinized as to the influence on those structures from tooth movement.¹² Displaying only the crowns of teeth in software simulations (whether for traditional orthodontic appliances or for aligner therapy) does not respect the periodontium attached to the crowns of teeth and does not provide transparency to unavoidable changes that occur within the dentoalveolar bone complex when tooth movement occurs. It is the periodontist's responsibility to define areas where hard and/or soft tissue augmentation will be needed and how much augmentation is possible to enhance dentoalveolar bone volume to which arch forms can be decompensated or corrected. This starts, in part, with an analysis of the mucogingival status with focus on the keratinized tissue width, gingival thickness, and presence/risk for recession^{16,17} after confirming a healthy oral situation relative to gingivitis or periodontitis, localized or generalized. Marginal tissue may be defined as thick versus thin. This group found that the most convenient approach is to use the phenotype probe visibility test. (Hu Friedy). It is important to define if the areas of soft tissue deficiencies are localized or generalized. Limited localized areas can be managed during the corticotomy-bone augmentation procedure. If there is generalized thin soft tissue, there should be concern about whether the thin tissue can sustain the bone augmentation procedure. If there are concerns, it is the consensus that a two-step

approach would be prudent. In this scenario, the panel varies on the type of grafting to be used, but the consensus is to thicken the gingival tissue and allow for 3 to 4 months of healing and revascularization.

The corticotomy-bone augmentation procedure is the critical part of this PhMT surgery. Interdental corticotomy and decortication of the alveolar housing creates a transient demineralization phase within the dentoalveolar complex, and the resulting soft tissue-bone matrix permits an accelerated rate of tooth movement because of an altered physiologic response known as the regional acceleratory phenomenon (RAP) effect.^{10,18,19} This injury results in acceleration of all processes involved in healing, including remodeling, cell turnover, metabolism, and repair. In individuals with thin bone morphotype, the movement of the teeth frequently results in bone loss (fenestrations, dehiscence's) and future gingival recession if RAP is not employed. By combining soft tissue augmentation and bone grafting techniques, it is possible to convert a thin to a thick gingival phenotype and bone morphotype. The interdental corticotomy is performed primarily at interdental sites, with burs or piezo surgical incision to a depth of at least 2 mm. The critical event is to extend the corticotomies beyond the cortical bone and into the medullary area. To date, devitalization of the tooth and damage to the root structures was reported in only one case by one panel member. The corticotomies and bone augmentation should be provided on the facial bone in the same direction of the tooth movement, that is on the pressure side. For example, if arch expansion is undertaken, the treatment is provided for the facial alveolar bone only. Contrary to previous reports, the corticotomy-dentoalveolar bone decortication need not be done on both buccal and lingual sides as it has been shown that the tension side of orthodontic tooth movement will respond with bone deposition. However, it should also be understood that injury to both sides may be required to achieve the desired tooth movement as McBride et al. has shown. The greater the surgical insult around the tooth will result in greater magnitude of the RAP produced.²⁰⁻²² Though each panelist has a preferred bone graft material protocol, all panelists believe in a collagen barrier is not necessarily for guided tissue regeneration purposes but for graft containment. The importance of flap closure and wound stability is emphasized. All believe in the use of long termed stabilization through the use of passive suturing.

Surgical healing is consistent with most regenerative and mucogingival grafting surgery. Infection is generally rare with the main adverse event consisting of incomplete root coverage. In extensive grafting with thin tissue thickness, superficial sloughing of the epithelium may be observed for the first few months, which requires monitoring but no immediate active management. Relapse of gingival recession, infrequently noted, is remedied with subsequent corrective mucogingival surgery such as additional subepithelial connective tissue grafts or augmentation with allograft substitute. The primary concern

TABLE 2 Comparison of SFOT/PAOO approach by the panelist

Procedure	Op 1	Op 2	Op 3
<i>Flap Management</i>	<ul style="list-style-type: none"> ■ Full thickness flap reflection but need to avoid excessive flap reflection for this allow more dissemination of the graft particles 	<ul style="list-style-type: none"> ■ Full thickness flap elevation. Flap elevation only for sites where tooth movement is treatment planned. If movement is to buccal then, only facial flap is reflected. If full bodily movement of a tooth is proposed, then both the facial and lingual tissue will be elevated. ■ Flaps are reflected to approx. 1 to 2 mm apical to tooth apex to help with containment of graft materials 	<ul style="list-style-type: none"> ■ Full thickness and broad dissection to identify vital structures/regional anatomy clarity. ■ Osseous surgery is performed, as needed) for esthetic crown enhancement on the facial aspect so that the dentogingival complex is set in the ideal position for tooth proportion display post-surgery.
<i>Corticotomy procedure</i>	<ul style="list-style-type: none"> ■ Used piezo to score on the buccal and #1/2 surgical round bur on lingual or to connect piezo cut. It's important to score through the cortical plate which may be ≥ 2.0 mm in thickness ■ Tendency to rely on piezo on the buccal and doing a "U" shape design. On the lingual, will do the "U" shape design when possible but in the mandibular canine areas, corticotomy design is often just parallel the root without the apical perpendicular cut if visibility is an issue ■ No complication/history of tooth/pulpal damage 	<ul style="list-style-type: none"> • Corticotomies are completed primarily in the interdental bone septae to a depth of 2 or more mm into medullary bone. • Piezo used exclusively for osseous cuts. • Coronal advance flap as needed for root coverage. • No complications 	<ul style="list-style-type: none"> ■ Interdental corticotomies made with 700, 701, or 702 carbide bur in straight handpiece ■ Apical cut made via semilunar design and 5 mm apical to tooth apex ■ Depth of corticotomies is 3 to 5 mm and intramarrow penetration confirmed ■ Osteoplasty (if needed) leading to dentoalveolar decortication performed with round diamond bur in straight handpiece or high speed handpiece. ■ No complications
<i>Management of recession and dehiscence</i> (Continued)	<ul style="list-style-type: none"> ■ No noticeable improvement with biologics including stem cell allograft³, rhPDGF⁴, nor enamel matrix derivative⁵. 	<ul style="list-style-type: none"> ■ Exposed recession areas are treated with EDTA⁶ +s/rp. 	<ul style="list-style-type: none"> ■ Emdogain is applied to dehiscid or fenestrated root surfaces followed by cancellous allograft

TABLE 2 (Continued)

Procedure	Op 1	Op 2	Op 3
Osseous grafting	<ul style="list-style-type: none"> ■ FDBA-superficial porous bone xenograft⁷ ■ Best results are when resorbable collagen GTR membrane is used for containment. ■ The critical trick is not to over reflect or the graft particle dispersal control is an issue. ■ Unsuccessful approaches: Previous use of DFDBA, FDBA, and stem cell allograft.³ Similar/less effective compare to present protocol. 	<ul style="list-style-type: none"> ■ DFDBA- porous bone xenograft⁷ (in 33 to 67% respective ratio) are effective ■ Place 3 to 4 mm of graft materials extending the apex of flap reflection ■ Secures a 4 to 5 mm wide strip of thin Acellular dermal matrix ^{t1} to lingual aspect of the buccal flap w 5/0 ePTFE (rapid) suture in a continuous tacking manner such that the coronal edge is 3 mm apical to the coronal to the buccal flap ■ Unsuccessful approaches: Minimal long-term success with PRF and has discontinued Have tried DFDBA-FDBA (50 to 50%) a little less volume gain 	<ul style="list-style-type: none"> ■ Corticocancellous allograft (particle size 0.25 to 1.0 mm or layered beyond cancellous allograft or directly onto facial alveolus. Graft is hydrated in PRF ■ Outer layer of bone graft is via porous bone xenograft⁷ (small particle size). Xenograft is hydrated in PRF. Porous bone xenograft⁷ is the xenograft of choice (Small particle size) ■ Horizontal bone volume added is proportional to tooth movement needs ■ Resorbable collagen membrane is trimmed and adapted over reconstructed area and fixated to place via tacks. 40 × 50mm collagen matrix membrane⁸ is the membrane of choice (one per arch) ■ Unsuccessful approaches: Previous strategies tried and abandoned: <ul style="list-style-type: none"> - collatope as membrane - no membrane - use of bone putty
Flap management	<ul style="list-style-type: none"> ■ Use 5-0 chromic cut in a continuous fashion to realign the papillae and used as stay suture. ■ Use 5-0 ePTFE simple suture to stabilize each papilla area and horizontal mattress pm starting on the lingual aspect to suspend the buccal flap at the appropriate height 	<ul style="list-style-type: none"> ■ Secure flap both horizontally and vertically w 5-0 ePTFE mattress sutures 	<ul style="list-style-type: none"> ■ ePTFE (if performing advanced GBR in an edentulous area) or 5-0 Monocryl sutures are used in the posterior with a sling design ■ Anterior sextant is sutured via 5-0 or 6-0 polypropylene via horizontal mattress design and monocryl via everting mattress at the interdental papillary areas to

■ Highlighted procedures are common therapeutic approaches shared by all OGS orthognathic surgery; TAD temporary anchorage devices Alloderm; 2. Mucograft; 3. Osteoceil; 4. PDGF; 5. Endogain; 6. PrefGel; 7. BioOss; 8 BioGid.

TABLE 3 Comparison of post-operative management by the panelist

Procedure	Op 1	Op 2	Op 3
<i>PO-Surgical management</i>	<ul style="list-style-type: none"> ■ Surgical complication consistent with extensive soft tissue grafting that consist of marginal sloughing/necrosis, incomplete root coverage for short termed (≤ 3 months) ■ Secondary soft tissue augmentation procedure may be necessary 6 mos. out ■ PO check at week 1, 2, 4, 8, 12 and then quarterly thereafter. ■ CBCT scan 1 year out and at end of treatment (2 to 3 years po) 	<ul style="list-style-type: none"> • Amoxicillin (500 g) qid x 5 days; Ibuprofen 600mg6h x 5 days • CHX rinses tid x 3 weeks • Norco (6 tab prn. Note: very few patients filled this script) • Sutures removed 2 to 3 weeks PO • OH assessment at 6 weeks PO with supra-gingival polishing • SPT at 3 months and alternate with GPs office • CBCT scan 12 months after • Seldom have complication but can be associated with of small localized area of sloughing which area managed with gentle debridement with supplemental CHX 	<ul style="list-style-type: none"> ■ Post-surgical visits occur at 1 to 2 weeks, 4 weeks, 8 to 12 weeks and 6 months. Sutures removed at 4 (posterior) or 8 weeks (polypropylene) ■ At 4 weeks, 8 weeks and 6 months, full mouth supragingival debridement is performed. 3 to 4 months are allowed for RAP phase tooth movement ■ Evaluate for revision mucogingival surgery as needed ■ CBCT post op at 6 months
<i>Orthodontic management</i>	<ul style="list-style-type: none"> ■ Arch wire is placed and activated right after 1 weeks post-op ■ Orthodontist management of movement every 2 to 3 weeks for first 3 months then once a month ■ Standard orthodontic analysis ■ May involve moving to a second phase of orthognathic surgery to complete ideal results ■ Periodontal maintenance q3 to 4 months until debanding. 	<ul style="list-style-type: none"> • Arch wire placed at the end of surgery 	<ul style="list-style-type: none"> ■ Archwires or aligned activated to take advantage of RAP at 1 to 2 weeks post SFOT surgery ■ Heavy archwires are replaced every 2 weeks ■ Aligners are changed every 3 days ■ Standard orthodontic analysis and outcome goals with expansion and non-extraction context preferred ■ Orthodontic decompensation planned to either manage malocclusion entirely or set case up for orthognathic surgery ■ Post SFOT restorative completed to set up tooth proportions and anatomy more optimally prior to orthognathic surgery ■ Orthognathic surgery as needed ■ Repeat WatchPAT analysis at treatment outcome to assess for UARS or OSA changes ■ Prosthetic phase completion, if needed ■ Periodontal maintenance q4 to 6 months



Highlighted procedures are common therapeutic approaches shared by all.

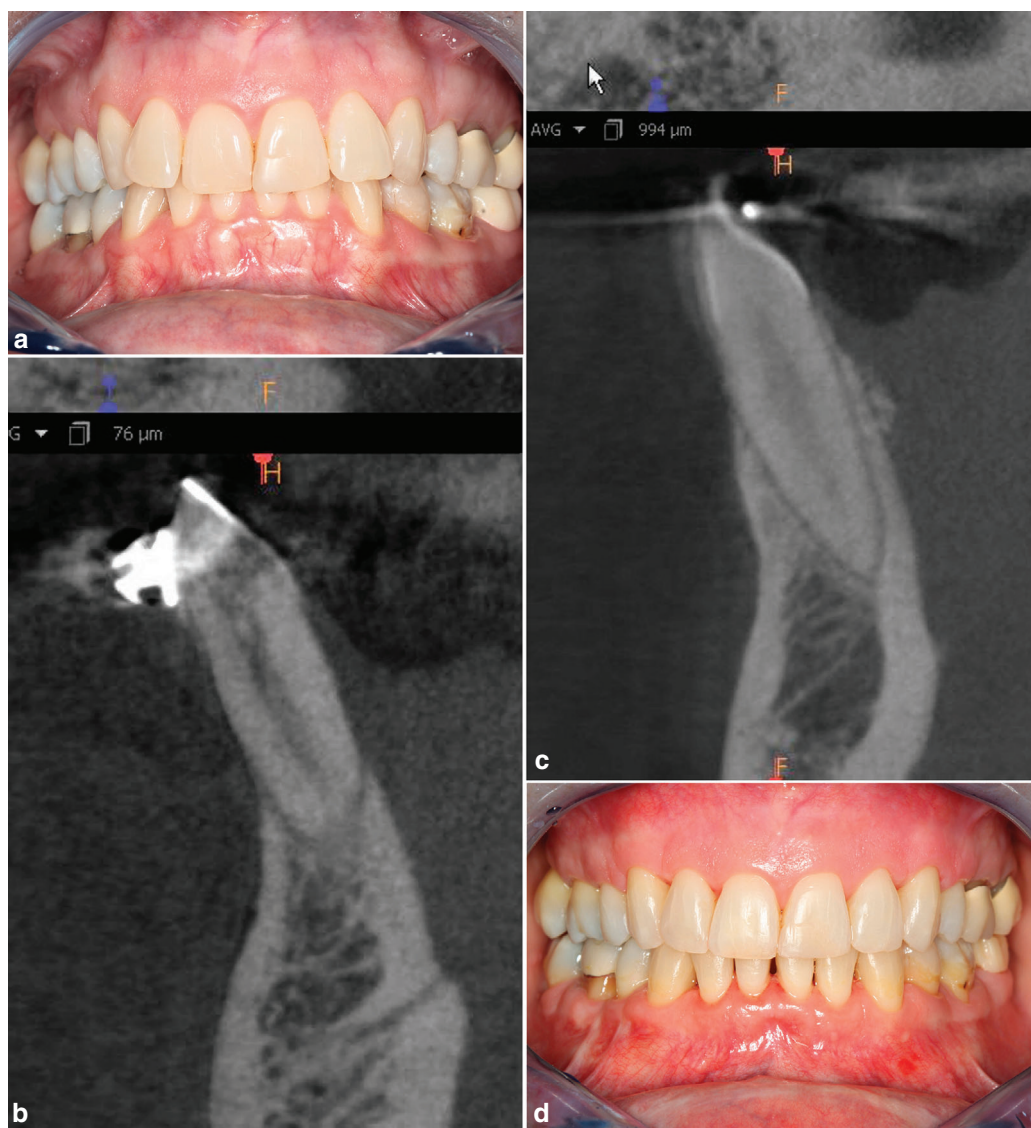


FIGURE 3 This is a SFOT case with a 10 + years. Follow-up. 3a) pre-op view. (note the “corrugated appearance” because of root prominences for the anterior teeth); 3b) CBCT of the lower anterior segment. (note the lack of supporting alveolar bone); 3c) post-op CBCT of the same area 14 mos. after SFOT; and 3d) clinical presentation after 10 + year. The “corrugated appearance” of the facial alveolar bone, seen in the pre-treatment image no longer evident in the post treatment clinical vies, because of bone augmentation. The orthodontic treatment did not result in the appearance of gingival recession.

post-operatively is to activate orthodontic forces after 1 to 10 days post-SFOT surgery. The arch wire should be activated within the first 2 weeks and usually adjusted every other week as needed.

Post-SFOT monitoring, both short term and long term include monitoring of the pocket depth, relapse of gingival recession, soft tissue thickness, increased appearance of bone thickness from CBCT views. This is confirmed with pre- and post-op CBCT obtained prior to treatment and after 1 or more years post treatment. As with any therapeutic approach, stability of long-termed outcome is important. This has been the consistent outcomes for this panel of clinicians (Fig. 3).

Though it would be ideal to have randomized control trials or prospective cohort designs, the risk of gingival recession, attachment loss, increased tooth mobility, and

risk for tooth loss does not permit this type of comparison. In this article, we have provided consensus opinions of three clinicians who have performed more than a total of 1500 cases their appreciation and prospective of the SFOT procedure.

Conclusion

SFOT is a PhMT that can open orthodontic treatment opportunities for a certain population of patients with malocclusion. The corticotomy-bone augmentation procedures are inherent to our periodontal training, but to master the use of SFOT in orthodontic treatment, an interdisciplinary team is essential to properly coordinate treatment sequencing, timing, surgical protocols, and address

the core problems of the patient. In this context, the interdisciplinary team uses the unique individual skillsets from each member on the team who is best suited and trained to manage each piece of the puzzle for the benefit of the patient. A decision tree has been proposed and developed from the experience of our panelist and is presented for the periodontal community's consideration.■

Acknowledgments

Participants filed detailed disclosure of potential conflicts of interest and there is no conflict of interest.

CORRESPONDENCE

Richard T. Kao, DDS, PhD, Orofacial Sciences, University of California San Francisco, San Francisco, CA
E-mail: richkao@sbcglobal.net

References

1. Chambrone L, Tatakis DN. Periodontal soft tissue root coverage procedures: a systematic review from the AAP regeneration workshop. *J Periodontol* 2015;86(Suppl 2):S8-S51.
2. Kim DM, Neiva R. Periodontal soft tissue non-root coverage procedures: a systematic review from the AAP regeneration workshop. *J Periodontol* 2015;86(Suppl 2):S56-S72.
3. Ferguson DJ, Wilcko MT, Wilcko WM, Makki L. Scope of treatment with periodontally accelerated osteogenics orthodontic therapy. *Seminars in Orthodontics* 2015;21:176-186.
4. Hoogveen EJ, Jansma J, Ren Y. Surgically facilitated orthodontic treatment: a systematic review. *Am J Orthod Dentofacial Orthop* 2014;145(4 Suppl):S51-64.
5. Wilcko MT, Ferguson DJ, Makki L, Wilcko W. Keratinized gingiva height increases after alveolar corticotomy and augmentation bone grafting. *J Periodontol*. 2015;86:1107-1115.
6. Mandelaris GA, DeGroot BS, Relle R, et al. Surgically facilitated orthodontic therapy: optimizing dentoalveolar bone and space appropriation for facially prioritized interdisciplinary dentofacial therapy. *Compendium* 2018;30:146-156.
7. Mandelaris et al. CAP (previous paper in CAP)
8. Mandelaris GA, Scheyer ET, Evans M, et al. American academy of periodontology's best evidence consensus statement on selected oral applications for cone-beam computed tomography. *J Periodontol* 2017;88(10):939-945.
9. Mandelaris GA, Neiva R, Chambrone L. American academy of periodontology best evidence consensus on cone beam computed tomography and interdisciplinary dentofacial therapy. A systematic review focusing on risk assessment of the dentoalveolar bone changes influenced by tooth movement. *J Periodontol* 2017;88(10):960-977.
10. Wilcko MT, Wilcko WM, Bissada NF. An evidence-based analysis of periodontally accelerated orthodontic and osteogenic techniques: a synthesis of scientific perspectives. *Semin Orthod* 2008;14:305-316.
11. Makki L, Ferguson DJ. Stability of mandibular irregularity index with and without PAOO: a review. *Adv Dent Oral Health* 2017;4:1-3.
12. Akay MC, Aras A, Gunbay T, Akyalcin S, Koyuncue BO. Enhanced effect of combined treatment with corticotomy and skeletal anchorage in open bite correction. *J Oral Maxillofac Surg* 2009;67:563-9.
13. Vercellotti T, Podesta A. Orthodontic microsurgery: a new surgically guided technique for dental movement. *Int J Periodontics Restorative Dent* 2007;27:325-331.
14. Frost HM. The biology of fracture healing. An overview for clinicians Part II. *Clin Orthop Relat Res* 1989;248:294-309.
15. Frost HM. The biology of fracture healing. An overview for clinicians. Part I. *Clin Orthop Relat Res* 1989;248:283-293.
16. Proffit WR. *Contemporary Orthodontics*. 4th ed. Mosby, St Louis 2007; 107-129 and 689-691.
17. Kim D, Bassit H, Nguyen T. Effect of gingival phenotype on the maintenance of periodontal health: an American Academy of Periodontology Best Evidence Review. *J Periodontol*. 2020;91(3):311-338.
18. Wang C-W, Yu S-H, Mandelaris GA, Wang H-L. Is phenotypic conversion therapy beneficial for patients receiving orthodontic treatment? An American Academy of Periodontology Best Evidence Review. Accepted to *J Periodontol*. 2020;91(3):299-310.
19. Ferguson DJ, Machado I, Wilcko MT, Wilcko W. Root resorption following periodontally accelerated osteogenic orthodontics. *APOS Trends Orthodontics* 2016;6:78-84.
20. Patterson BM, Dalci O, Darendeliler A, et al. Corticotomies and orthodontic tooth movement: a systematic review. *J Oral Maxillofac Surg* 2016;74:453-473.
21. Murphy KG, Wilcko MT, Wilcko WM, Ferguson DJ. Periodontal accelerated osteogenic orthodontics: a description of the surgical technique. *J Oral Maxillofac Surg* 2009;67:2160-2166.
22. McBride MD, Campbell PM, Opperman LA, et al. How does the amount of surgical insult affect bone around moving teeth? *Am J Orthod Dentofacial Orthop*. 2014;145:S92-S99.

○ indicates key references.